



**PRESENTING CLINICAL SIGNS**

History: Presented for coughing. No murmur. Minimal response to doxycycline and butorphanol.

**DATE**

12/1/22

**ECHOCARDIOGRAPHIC FINDINGS**

2D, M-mode, and Doppler study.

**PERFORMED BY:**

Kelly Vazquez

Left atrial size is normal. The mitral valve is normal. Left ventricular dimensions are normal. Left ventricular systolic function is hyperdynamic. The aorta and aortic valve appear normal, though trace aortic insufficiency is present. Right atrial and right ventricular dimensions are normal. The tricuspid valve is normal. The pulmonary artery and pulmonic valve are normal. No shunting lesions are visualized. No pericardial effusion or cardiac masses are seen.

**INTERPRETED BY**

Keith Blass, DVM,  
MS, DACVIM  
(Cardiology)

LA - 21.4 mm  
LVIDd - 18.7 mm  
LVIDs - 9.9 mm  
FS - 47%  
LVOT - 1.39 m/s  
RVOT - 0.95 m/s

**PATIENT**

Chewy Gregorowski

**ASSESSMENT/RECOMMENDATIONS**

Normal echocardiogram

**SPECIES**

Canine

This examination demonstrates no evidence of structural heart disease, as trace aortic insufficiency can be considered a normal physiologic variant. As such, no reason for Chewy's cough is appreciated in the image set.

**BREED**

Chihuahua

No therapy is recommended based on this exam.

A recheck echocardiogram is recommended if new physical exam and/or clinical abnormalities suggestive of cardiac dysfunction develop.

**SEX**

**MN**

**AGE**

11 y

**WEIGHT**

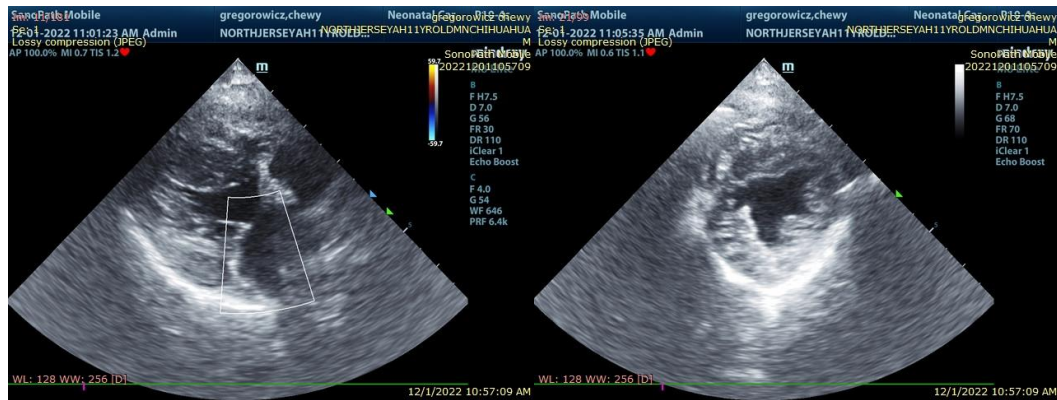
10.2 lb

**HOSPITAL NAME**

North Jersey AH

**REFERRING VET**

Dr. Shaw



The information and recommendations provided are based on the images presented by the referring veterinarian. No evaluation can be communicated regarding pathology that was not visible in the image/video clips provided.

Thank you for this referral. If the clinical or image interpretation does not parallel your findings or



if I can be of any further assistance please contact me.

**DATE**

12/1/22

**Keith Blass, DVM, MS, DACVIM (Cardiology)**

KeithBlass@gmail.com

631-804-5754

**PERFORMED BY:**

Kelly Vazquez

**INTERPRETED BY**

Keith Blass, DVM,  
MS, DACVIM  
(Cardiology)

**PATIENT**

Chewy Gregorowski

**SPECIES**

Canine

**BREED**

Chihuahua

**SEX**

MN

**AGE**

11 y

**WEIGHT**

10.2 lb

**HOSPITAL NAME**

North Jersey AH

**REFERRING VET**

Dr. Shaw